

Identification of non-tuberculous mycobacteria isolated from opossum (*Didelphis virginiana*) lymph nodes and characterisation of lesions

Luis J. García^{a*}, David A. González^b, Omar F. Prado^b, Julio R. Macedo^b,
R Ramírez^c, J Martínez^d, Hugo B. Barrios^d, A López^e, F Constantino^f

ABSTRACT. The aim of this study was to investigate the presence of NTM in the lymph nodes of opossums (*D. virginiana*) and to characterise the microscopic changes in affected tissue. Retropharyngeal and tracheobronchial lymph nodes were collected *postmortem* from 18 opossums in the state of Colima, Mexico in 2013. The lymph nodes were also cultured for mycobacterial organisms and processed for histopathological examination. Bacteriological cultures yielded 5/18X100 (28%) isolates of NTM, which were subsequently identified as *M. terrae*, *M. szulgai*, *M. gastri* and *M. asiaticum*. Microscopic examination of the affected nodes revealed a necrotic granulomatous lymphadenitis (3/60%) composed of histiocytes, epithelioid cells and giant cells with intralésional alcohol-resistant acid bacteria. An association between the sex of the opossum and the presence of NTM was observed. To our knowledge, this is the first report of NTM isolation in opossums with granulomatous lymphadenitis in Mexico.

Key words: mycobacteria, tuberculosis, opossums, lesions.

RESUMEN. El objetivo de este estudio fue investigar la presencia de MNT en los nódulos linfáticos de los tlacuaches (*Didelphis virginiana*) y caracterizar los cambios microscópicos en el tejido afectado. Se recolectaron 18 *D. virginiana* en el estado de Colima, México, en 2013. Los nódulos linfáticos retrofaríngeos y traqueobronquial fueron procesados para aislamiento de micobacterias e histopatología. Se obtuvieron 5 aislamientos de MNT (5/18X100=28%), de entre estos destacan las especies de *M. terrae*, *M. szulgai*, *M. asiaticum* y *M. gastri*. El examen microscópico de los nodos afectados reveló una linfadenitis necrótica granulomatosa (3/60%) compuesta de histiocitos, células epitelioides y células gigantes con bacterias ácido alcohol resistente intralésional. Se encontró una relación entre las MNT y el sexo de los tlacuaches. Este es el primer informe de aislamiento de MNT en los tlacuaches con linfadenitis granulomatosa en México.

Palabras clave: micobacteria, tuberculosis, tlacuache, lesión.

INTRODUCTION

There are more than 130 species of nontuberculous mycobacteria (NTM), also known as atypical or environmental mycobacteria. These opportunistic bacteria are regular inhabitants of soil, water, earth and inanimate objects. They are well distributed in our environment and have great pathogenic potential, with a clinical profile or lesions similar to those caused by tuberculosis (Casal and Casal 2000, Gadkowski and Stout 2008, Koneman *et al* 2008). Infections by NTM have been reported from clinical cases in humans as well as domestic and wild animals (Bercovier and Vincent 2001). The NTM bacteria important to humans are *M. kansasii*, *M. genavense*, *M. marinum*, *M. simiae*, *M. scrofulaceum*, *M. szulgai*, *M. avium*, *M. haemophilum*,

M. intracellulare, *M. malmoense*, *M. ulcerans*, *M. xenopi*, *M. abscessus*, *M. chelonae*, *M. fortuitum* and *M. smegmatis* (Holland 2001, Iseman and Marras 2008, Piersimoni and Scarparo 2008). The species *M. chelonae-abscessus* and *M. flavescens* cause cutaneous lesions in cats and dogs (Jang and Hirsh 2002). In bovines, the NTM species that have been isolated are *M. gastri*, *M. flavescens*, *M. phlei*, *M. triviale*, *M. terrae*, *M. nonchromogenicum*, *M. intracellulare*, *M. gordonae*, *M. thermoresistibile*, *M. xenopi*, *M. fortuitum*, *M. chelonae*, *M. szulgai*, *M. ulcerans* and *M. kansasii* (Proano *et al* 2006, Hernández 2014). The species *M. marinum* and *M. kansasii* have been isolated from wild animals such as manatees (*Trichechus manatus latirostris*) (Sato *et al* 2003). In addition, *M. kansasii* has been isolated from black-tailed deer (*Odocoileus hemionus columbianus*) (Hall *et al* 2005). The lymph nodes of the head are the tissues of choice for tuberculosis inspection in wild boar, since the diagnosis of the mycobacteria can be done just by observing these nodes in more than 90% of the infected population (Martín *et al* 2007). The aim of this study was to investigate the presence of NTM in the lymph nodes of opossums (*D. virginiana*) and to characterise the microscopic changes in affected tissue.

MATERIAL AND METHODS

HOST COLLECTION AND NECROPSY

During 2013, eighteen road-killed *D. virginiana* were collected in the state of Colima, Mexico. The site was located

Accepted: 03.05.2017.

^aCentro Universitario de Investigación y Desarrollo Agropecuario (CUIDA), Universidad de Colima, Colima, México.

^bFacultad de Medicina Veterinaria y Zootecnia de la Universidad de Colima, Colima, México.

^cDepartamento de Patología de la Facultad de Medicina Veterinaria y Zootecnia de la Universidad Autónoma de Nuevo León, Nuevo León, México.

^dDepartamento de Patología de la Facultad de Medicina Veterinaria y Zootecnia de la Universidad Autónoma de Tamaulipas, Tamaulipas, México.

^eDepartment of Pathology and Microbiology Atlantic Veterinary College, University of Prince Edward Island, Prince Edward Island, Canada.

^fDepartment of Veterinary Medicine, University of Cambridge, Cambridge, UK.

*Corresponding author: LJ García; Crucero de Tecoman, Km 40 carretera Colima-Manzanillo, CP: 28100, México; ljgm_cmv@hotmail.com

at 19°41' -19°16' N, 102°46' -103°47' W, with an altitude of 500 meters (INEGI 2010)¹. A necropsy identified lesions suggestive of tuberculosis. Homologous tissue sections collected from the tracheobronchial and retropharyngeal lymph nodes were preserved in a 6% borate solution (Pronavibe-SAGARPA) and 10% buffered formalin.

BACTERIOLOGY

After the sodium borate and the excess fat were removed, the lymphoid tissue was cut into small pieces in a sterile mortar; sterile sand was added, and the tissue was manually macerated. The liquid was decanted in a 1:1 proportion into a 4% sodium hydroxide solution with phenol red, and then it was incubated at 37 °C for 20 minutes, after which it was centrifuged at 3000 x g for 20 minutes. The sediment was deposited in a sodium hypochlorite solution, which was then neutralised with a 1 N hydrochloric acid solution until a shift in the color (from pink to yellow) was observed.

Three cultures were seeded in two tubes of Stonebrink (Pronavibe) culture medium and one tube of Lowenstein-Jensen medium (Pronavibe), which were then incubated at 37 °C for 24 hours. After 24 hours, they were incubated at 37 °C under a 5% CO₂ atmosphere for 9 weeks. The growth obtained was verified using the Ziehl-Neelsen stain.

The isolates were identified based on their characteristics and growth morphology as well as metabolic activity, specifically, niacin production, nitrate reduction, catalase activity at 22 °C and 68 °C, urea activity, TWEEN 80 hydrolysis, growth on MacConkey agar without crystal violet and 5% NaCl tolerance. All isolates were seeded in four replicates. The four replicas were incubated for 30 days under different conditions: one culture was incubated at 22 °C, another at 45 °C and two at 37 °C under a 5% CO₂ atmosphere, one in the absence of light and another in the presence of light.

HISTOLOGY

The lymph nodes were assessed for the presence of NTM. They were embedded in paraffin; 4.0-micron-thick sections were cut and stained with hematoxylin-eosin (H and E), and Ziehl-Neelsen (ZN) (Prophet *et al* 1995).

STATISTICAL ANALYSIS

A chi-squared test was performed to evaluate the association between the sex of the opossum and the presence of NTM, and the prevalence rates were expressed as percentages.

The work was subject to the provisions of the Official Mexican Standard: NOM-033- ZOO-1995² y NOM-051-ZOO-1995³.

RESULTS AND DISCUSSION

Eighteen *D. virginiana* were collected, of which 7/18 (39%) were female and 11/18 (61%) were male. Five out of the 18 animals (28%) were positive for the isolation of NTM, and three of them presented granulomatous lesions in their lymph nodes. The NTM isolated corresponded to the species *Mycobacterium szulgai*, *M. terrae*, *M. asiaticum* and *M. gastri* (table 1 and figure 1). An association was found between the sex of the animal and its NTM status: infection was more frequent in males of *D. virginiana* (table 2). The distribution of NTM in the environment and their importance as opportunistic pathogenic organisms or even strict pathogens in humans, domestic animals and wild animals have been reported as sources of the disease called mycobacteriosis (García and García 2012). The role of NTM does not appear anywhere in the research literature about *D. virginiana*; however, life habits imply a strong interaction between them and their environment due to their varied diet and their behaviour and distribution patterns. These habitat interactions facilitate the presence of NTM in *D. virginiana*, which could eventually become a wild reservoir of the bacteria, hindering the microbiological isolation of the complex of mycobacteria when mixed infections exist. It has also been proved that some NTM interfere with today's official diagnostic tests for bovine tuberculosis due to cross-reactivity (Jaroso *et al* 2010).

The problem with this interference in the epidemiological study of bovine tuberculosis in Mexico is that despite 21 years of efforts to eradicate the disease, only 82% of the national territory has less than 0.5% prevalence of bovine tuberculosis (NOM-031-ZOO-1995)⁴. The association between sex and the presence of NTM is due to *D. virginiana* having a sex ratio of 1:1, which is considered an ideal condition for population growth. However, in polygamous species such as *D. virginiana*, there tends to be a larger number of males, especially in zones where resources are more available, and competition is far less stringent. In these zones, it is believed that the sex ratio observed could be associated with the size of the population and the distribution patterns of the species, which are determined primarily by competence, predation, availability of food resources, shelter, immigration, dispersion and extinction (Cruz *et al* 2014). The wild boar is considered the most

² NOM-033-ZOO-1995. Sacrificio humanitario de los animales domésticos y silvestres. <http://www.senasica.gob.mx/?doc=529>.

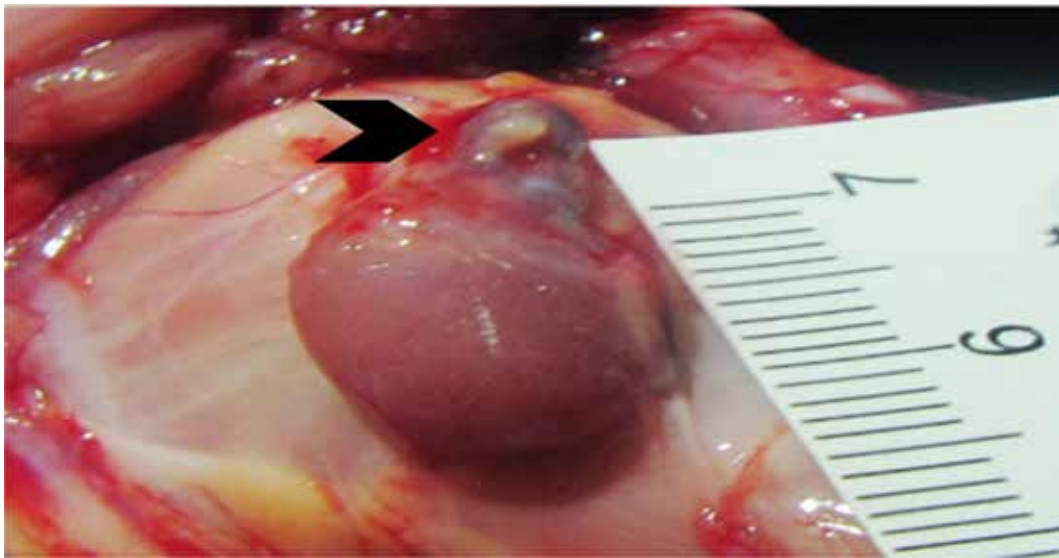
³ NOM-051-ZOO-1995. Trato humanitario en la movilización de animales. <http://www.senasica.gob.mx/?doc=531>.

⁴ NOM-031-ZOO-1995. Campaña Nacional contra la Tuberculosis Bovina (*Mycobacterium bovis*). <http://www.senasica.gob.mx/?doc=725>.

¹ INEGI, Instituto Nacional de Estadística y Geografía. 2010; <http://www.inegi.org.mx/inegi/default.aspx?s=geo&e=06>.

Table 1. *D. virginiana* positive for nontuberculous mycobacteria (NTM), and histological lesions of retropharyngeal lymph nodes and positive to Ziehl Neelsen originated in the State of Colima, Mexico, in 2013.

Sex	Locality-Location	Classification of NTM	Ziehl Neelsen	Granuloma Lesion
Male	Tecomán 18°55'N104°31'O	<i>M. szulgai</i>	Yes	Yes
Female	Tecomán 18°55'N104°31'O	<i>M. terrae</i>	No	No
Male	Colima 19°15'N103°43'O	<i>M. asiaticum</i>	No	Yes
Male	Manzanillo 19°31'N104°19'O	<i>M. gastri</i>	No	No
Male	Tecomán 18°55'N104°31'O	<i>M. terrae</i>	Yes	Yes

**Figure 1.** Retropharyngeal lymph node of *D. virginiana* in which a nodule can be observed in the cortical region. It measures 8X8 mm, well-defined, solid and brown (see the pointing arrow).**Table 2.** Association between the sex of *D. virginiana* and the presence of Non-tuberculous Mycobacteria (NTM) in the state of Colima, Mexico.

Sex	Positive		Negative		Chi-square	P
	N	%	n	%		
Male	4	36.36	7	63.64	12.95	0.00
Female	1	14.29	6	85.71		

important reservoir of tuberculosis, and it is primarily accountable for transmitting the disease to red deer (*Cervus elaphus*) and fallow deer (*Dama dama*) (García *et al* 2013). In Spain, diversity and co-infections of NTM and *M. bovis* in wild boar, fallow deer, red deer and cattle (in the south) have been described (Gortázar *et al* 2011). The NTM *M. chelonae* and *M. avium* have been isolated from wild boar (García *et al* 2015). Wild animals infected with

Mycobacterium spp. may, under certain conditions, become reservoirs of such agents. In the wild, the badger, deer, opossum, ferret and buffalo are recognised as reservoirs of bovine tuberculosis (Machackova *et al* 2003).

In this study, we present the finding of four NTM species that nevertheless produce similar granulomatous lesions. Therefore, the opossum *D. virginiana* could become a reservoir of *Mycobacterium* spp. for wild and domestic animals.

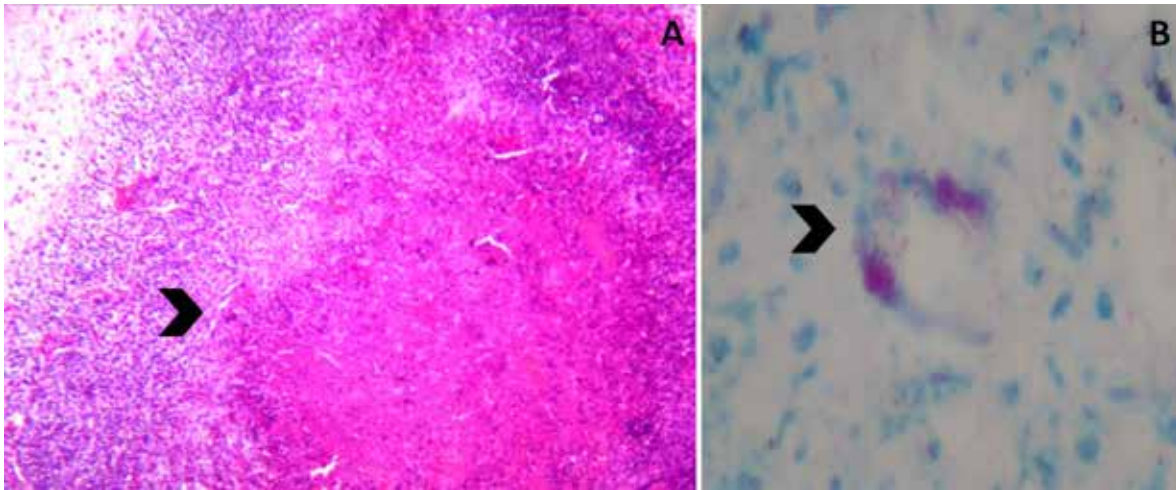


Figure 2. Retropharyngeal lymph node of *D. virginiana*. A. Presence of a granuloma with central necrosis (see the arrow). Hematoxylin-eosin staining. B. A giant Langhans type cell with Ziehl-Neelsen positive bacteria (see the arrow). Ziehl-Neelsen staining. Objectives: A=10X and B=40X.

The risk represented by *D. virginiana* is determined by its interaction with the environment due to its habitat, eating habits and behavioral patterns that expose it to mycobacteria present in environments such as water, soil, plants and animals; their coexistence with domestic animals and even with humans can spread these mycobacterial infections. This could facilitate a high presence of NTM in the lymph nodes of these animals, so it is useful to verify the presence, prevalence and variety of NTM in opossums in areas where bovine tuberculosis is endemic. These cases indicate that NTM can cause tuberculosis-like disease in *D. virginiana* and illustrates the importance of identifying causal agents of tuberculosis-like diseases in wildlife.

The lesions in the lymph nodes consisted of granulomas characterised by histiocytes, epithelial cells and giant cells; in two of the animals, acid-fast bacteria (ZN+) were observed (table 1 and figure 2). Granulomatous lesions associated with NTM have been described in black-tailed deer (Hall *et al* 2005), and granulomas in the lymph nodes of *D. virginiana* caused by *M. bovis* have been described in Mexico (Acosta *et al* 2012). Two types of lesions, pyogranulomatous and granulomatous, have been classified in the lymph nodes of bovines in Mexico where NTM were isolated (Hernández 2014). Depending on the susceptibility of the host, granulomas caused by mycobacteria in the wild can vary in size and may or may not be well delimited by connective tissue. The literature contains a great variety of descriptions of the types of lesions (macroscopic) and granulomas (microscopic) observed in wild fauna (Zanella *et al* 2008, García *et al* 2012). Granulomatous lesions in the lymph nodes and lungs of *D. virginiana* caused by mycobacteria could be confused with lipid pneumonia, as it manifests with whitish multifocal lesions on the lung parenchyma, which are common in opossums with the lung parasite *Didelphostrongylus hayesi* (García *et al* 2012).

Another parasite similar to *Paragonimus mexicanus* causes granulomatous pneumonia in opossums (García *et al* 2010).

ACKNOWLEDGEMENTS

Higher Education Subsecretary, Graduate-Promep Improvement Program SEP. REFASI Academic Network; Identification of the *Mycobacterium tuberculosis* complex in Mexican wildlife. Its role as a disease reservoir.

REFERENCES

- Acosta R, Ocampo J, Arellano Z, Ramírez L, Martínez V, *et al*. 2012. Histopathological and PCR *Mycobacterium bovis* Identification in Mexican Opossums (*Didelphis virginiana*) from Hidalgo, Mexico. *J Anim Vet Adv* 11, 207-210.
- Bercovier H, Vincent V. 2001. Mycobacterial infections in domestic and wild animals due to *Mycobacterium marinum*, *M. fortuitum*, *M. chelonae*, *M. porcinum*, *M. farcinogenes*, *M. smegmatis*, *M. scrofulaceum*, *M. xenopi*, *M. kansasii*, *M. simiae* and *M. genavense*. *Rev Sci Tech* 20, 265-290.
- Casal M, Casal M. 2000. Las micobacterias atípicas como patógenos emergentes. *Enf Em* 2, 220-230.
- Cruz B, Ruiz L, Navarrete D, Espinoza E, Vázquez E, *et al*. 2014. Genetic diversity and relative abundance of *Didelphis marsupialis* and *Didelphis virginiana* in Chiapas, Mexico. *Rev Mex Bio* 85, 251-261.
- Gadkowski B, Stout E. 2008. Cavitory pulmonary disease. *Clin Microbiol Rev* 21, 305-33.
- García L, Vázquez J, Sarabia D, León V, García L, *et al*. 2010. Lesiones pulmonares en tlacuaches (*Didelphis virginiana*) infectados naturalmente por *Paragonimus mexicanus* en Colima, México. *Vet Méx* 41, 65-72.
- García ML, López RA, López A, Prado OF. 2012. Neumonía lipídica endógena en tlacuaches (*Didelphis virginiana*) capturados en el estado de Colima, México. *Vet Mex* 43, 241-246.
- García MP, García L. 2012. Infections due to rapidly growing mycobacteria. *Enf Inf Microbiol Clin* 30, 192-200.
- García WL, Fernández P, Gómez L, Benítez J, García A, *et al*. 2012. Histological and immunohistochemical characterisation of *Mycobacterium bovis* induced granulomas in naturally infected Fallow deer (*Dama dama*). *Vet Immunol Immunop* 149, 66-75.

- García WL, Fernández P, Benítez J, Cerratos R, Cuesta J, *et al.* 2013. Reducing Eurasian wild boar (*Sus scrofa*) population density as a measure for bovine tuberculosis control: Effects in wild boar and sympatric fallow deer (*Dama dama*) population in Central Spain. *Prev Vet Med* 110, 435-446.
- García WL, Benítez J, Martínez R, Carranza J, Cerratos R, *et al.* 2015. Non-tuberculous mycobacteria in wild boar (*Sus scrofa*) from Southern Spain: epidemiological, clinical and diagnostic concerns. *Transb Emerg Dis* 62, 72-80.
- Gortázar C, Torres M, Acevedo P, Aznar J, Negro J, *et al.* 2011. Fine-tuning the space, time, and host distribution of mycobacteria in wildlife. *BMC Microbiol* 11, 1-16.
- Hall B, Bender C, Garner M. 2005. Mycobacteriosis in a black-tailed deer (*Odocoileus hemionus columbianus*) caused by *Mycobacterium kansasii*. *J Zoo Wildlife Med* 36, 115-116.
- Hernández JA. 2014. Identificación de micobacterias no tuberculosas aisladas de nódulos linfáticos de bovinos y caracterización de lesiones asociadas. *Tesis Maestría en Ciencias Veterinarias y Zootécnicas*, Facultad de Medicina Veterinaria y Zootecnia, Universidad Autónoma de Tamaulipas, México.
- Holland M. 2001. Nontuberculous mycobacteria. *Am J Med Sci* 321, 49-55.
- Iseman D, Marras K. 2008. The importance of non-tuberculous mycobacterial lung disease. *Am J Resp Crit Care Med* 178, 999-1000.
- Jang S, Hirsh C. 2002. Rapidly growing members of the genus *Mycobacterium* affecting dogs and cats. *J Am Anim Hosp Assoc* 38, 217-220.
- Jaroso R, Vicente J, Martín MP, Aranz A, Lyshchenko K, *et al.* 2010. Ante-mortem testing wild fallow deer for bovine tuberculosis. *Vet Microbiol* 146, 285-289.
- Koneman W, Winn C, Allen D, Janda M, Procop W, *et al.* 2008. *Diagnóstico Microbiológico. Médica Panamericana*. Buenos Aires, Argentina.
- Machackova M, Matlova L, Lamka J, Smolik J, Melicharek I, *et al.* 2003. Wild boar (*Sus scrofa*) as a possible vector of mycobacterial infections: review of literature and critical analysis of data from Central Europe between 1983 to 2001. *Vet Med Czech* 48, 51-65.
- Martín HMP, Höfle U, Vicente J, Ruiz F, Vidal D, *et al.* 2007. Lesions associated with *Mycobacterium tuberculosis* complex infection in the European wild boar. *Tubercle* 87, 360-367.
- Piersimoni C, Scarparo C. 2008. Pulmonary infections associated with non-tuberculous mycobacteria in immunocompetent patients. *Lancet Infect Dis* 8, 323-334.
- Proano F, Rigouts L, Brandt J, Dorny P, Ron J, *et al.* 2006. Preliminary observations on *Mycobacterium* spp. in dairy cattle in Ecuador. *Am J Trop Med Hyg* 75, 318-323.
- Prophet E, Mills B, Arrington J, Sobin H. 1995. *Métodos Histotecnológicos*. Washington DC: Instituto de Patología de las Fuerzas Armadas de los Estados Unidos de América (AFIP) y Registro de Patología de los Estados Unidos de América (ARP).
- Sato T, Shibuya H, Ohba S, Nojiri T, Shirai W. 2003. Mycobacteriosis in two captive Florida manatees (*Trichechus manatus latirostris*). *J Zoo Wildlife Med* 34, 184-188.
- Zanella G, Duvauchelle A, Hars J, Moutou F, Boschirolu ML, *et al.* 2008. Patterns of lesions of bovine tuberculosis in wild red deer and wild boar. *Vet Rec* 163, 43-47.

