

Accidental and late parasitological diagnosis of *Leishmania* sp. in a dog from a low disease transmission area of Brazil: a case report

Renan M. Spinelli^a, Flávia F.M. Uchôa^b, Rodrigo C. Menezes^c,
Fernanda N. Santos^d, Adriana P. Sudré^{a*}

ABSTRACT. Canine Leishmaniasis diagnosis must be fast and accurate since dogs are urban reservoirs of the disease and earlier therapeutic intervention is more clinically effective. However, this still represents a challenge, particularly in low transmission areas. The present report describes the difficulties of clinical suspicion and the late diagnosis of a dog infected with *Leishmania* sp.

Key words: canine leishmaniasis, late diagnosis, low transmission area.

Visceral Leishmaniasis (VL) is a vector-borne parasitic disease. In India and East Africa, VL is anthroponotic and caused by *Leishmania (Leishmania) donovani*, whereas in Europe and South America it is a zoonotic disease, caused by *Leishmania (Leishmania) infantum*. In the last two continents, dogs act as domestic reservoirs in rural and urban endemic areas (Ribeiro *et al* 2018). The arthropods related to the transmission of the parasite are from different genus in the Old and New Worlds. Sandflies of the genus *Phlebotomus* are responsible for the transmission in the old continents, while arthropods of the genus *Lutzomyia* transmit the protozoan in the New World. In Brazil, *Lutzomyia (Lutzomyia) longipalpis* is the main vector. Recently, it has been noticed that the epidemiological profile of VL is changing in Brazil. Previously, VL was known to be endemic in Brazilian rural areas, however, in recent years cases are being reported in urban areas (Marcondes and Day 2018).

The precise diagnosis, as well as the identification of infected dogs, are extremely important to the epidemiological control of the disease since the detection of canine cases usually precedes the appearance of the disease in humans (Marzochi *et al* 1985). Nonetheless, the paucity of information and knowledge related to the canine disease in low transmission areas, associated with non-specific clinical signs presented by the animals make the identification of infected dogs a diagnostic challenge. These facts end up

to negatively interfere in the control of the expansion of the disease (da Silva *et al* 2015).

The present report describes the occurrence of a canine leishmaniasis case (CanL) in the city of Niterói, Rio de Janeiro (RJ), Brazil, and aims to demonstrate the difficulties of a definitive diagnosis of a chronic and multisystemic disease that presents variable and non-specific clinical manifestation.

A female, 2 years old and pregnant French bulldog, born in Fortaleza-CE, was acquired by a person living in Niterói city, RJ. A few weeks after the acquisition, the dog presented a lack of appetite and prostration and was checked by a veterinarian. During the clinical examination, the only change observed was splenomegaly. The patient had no skin lesions or enlarged lymph nodes. At this moment blood was collected for further investigations. The complete blood count (CBC) results demonstrated: poorly regenerative normocytic normochromic anaemia, leucopenia and thrombocytopenia. No alteration was evidenced for: alanine aminotransferase (ALT), alkaline phosphatase (ALP), creatinine and urea, as well as there was no presence of haemoparasites at the examination of the sample through the Knott method and buffy coat smears. The results of the laboratory analysis performed can be observed in table 1.

Despite the absence of ticks in the patient and the incomplete clinical history, it was suspected that the dog presented canine monocytic ehrlichiosis. No serologic test was performed, the therapeutic decision was made based on the cytopenias observed in the CBC counts and in the fact that the region is endemic to tick-borne diseases (Labarthe *et al* 2003). Doxycycline 10 mg/kg/24h was prescribed and the animal's clinical condition improved after 21 days of treatment. No haematological changes were observed in the CBC after the treatment (table 1). Then, the clinical condition worsened, culminating with the resorption of the fetuses, verified by ultrasound examination, where it was also observed splenic hyperplasia.

A splenectomy was performed, the organ was sent to histopathologic evaluation and diagnosed with splenic infarction with haemorrhage. There was no clinical improvement

Received: 16.04.2019.

Accepted: 08.07.2019.

^aDepartamento de Microbiologia e Parasitologia, Universidade Federal Fluminense, Niterói, Brasil.

^bLaboratório Clínico Veterinário Flávia Uchôa, Niterói, Brasil, Rio de Janeiro, Brasil.

^cFundação Oswaldo Cruz, Instituto Nacional de Infectologia Evandro Chagas, Laboratório de Pesquisa Clínica em Dermatozoonoses em Animais Domésticos, Rio de Janeiro, Brasil.

^dFundação Oswaldo Cruz, Escola Nacional de Saúde Pública Sergio Arouca, Departamento de Ciências Biológicas Laboratório de Imuno-diagnóstico, Rio de Janeiro, Brasil.

*Corresponding author: AP Sudré; Rua Hernani Melo 101, ZIP 24210-130, São Domingos, Niterói, Brasil; asudre@id.uff.br

Table 1. Complete blood count results.

Serial results	1	2	3	4	5	6	7
	20-5-14	10-06-14	24-06-14	01-08-14	05-08-14	06-08-14	10-08-14
Red blood cells ($\times 10^3/\mu\text{L}$)	3.24	3.80	4.16	1.93	2.30	2.46	1.82
Hematocrit (%)	23.4	26.6	29.5	12.7	16.0	22.9	12.8
White blood cells ($\times 10^3/\mu\text{L}$)	3.3	3.2	4.8	5.1	11.2	16.0	8.8
Platelets ($\times 10^3/\mu\text{L}$)	38	52	92	44	95	96	115
Total Plasma Protein (g/dL)	>12.0	>12.0	8.8	10.2	11.2	11.8	>12.0

after the surgery, and two weeks after the procedure another CBC demonstrated that the blood cytopenias persisted. At this moment, the sample analysed presented microfilariae similar to *Dirofilaria immitis*, leading to a second treatment with doxycycline, associated with dexamethasone 1 mg/kg/24h and milbemycin 0.5 mg/kg/each month.

After three weeks without response to treatment, the dexamethasone dose was raised to 2 mg/kg/24h. A new CBC demonstrated the presence of haemagglutination, suggesting immune-mediated haemolytic anaemia, and it was observed an increase in ALT and ALP. The measurement of total protein and its fractions demonstrated a significant increase in globulins, with a decrease in the albumin/globulin ratio. Ascites was noticed and the microscopic analysis of the fluid evidenced structures similar to amastigote forms of *Leishmania* sp. Indirect Immunofluorescence (ImunoTeste®, Imunodot Diagnósticos, Brasil) (figure 1) and ELISA/S7-Kit® (Biogene, Brasil - antigen based on S7 fragment of recombinant peptide HSP70 of *Leishmania (Leishmania) infantum*) were performed to reinforce the cytological diagnosis of CanL. Both tests were positive, and the antibody titer detected by IFI was 1/80. According to Guidelines for diagnosis and clinical classification of leishmaniasis in dogs (Paltrinieri *et al* 2010), this patient

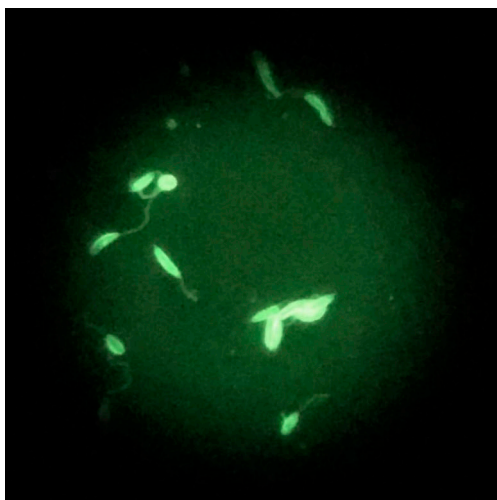


Figure 1. Indirect Immunofluorescence for *Leishmania infantum* (ImunoTeste®, Imunodot Diagnósticos, Brasil) positive result in a serum sample.

was at stage B of the disease. The animal died naturally after a few days.

The spleen material preserved in a paraffin section was sent to Fiocruz to perform new analyses. The histopathology revealed severe and diffuse granulomatous splenitis. No *Leishmania* sp. amastigote was detected at the histopathological test, however, results of the immunohistochemical exam (Tafuri *et al* 2004) were positive (figure 2).

Since the history and samples used in the present study were collected and donated by Flávia Uchôa Veterinary Clinical Laboratory, with the consent of the guardian of the animal, it was not necessary to obtain approval from the animal ethics committee.

The present report demonstrates a history and clinical signs consistent with CanL that was not identified due to the low specificity of the symptoms and the absence of cases of this disease in the clinical routine of veterinarians from the studied area. The region presents a high incidence of other diseases, such as dirofilariosis and ehrlichiosis (Labarthe *et al* 2003) and for this reason, it was a mistake not to consider the patient's history and attempt to diagnose the condition by using few support tools when a pre-established treatment for these diseases was prescribed. This fact demonstrates how difficult is to diagnose CanL in low transmission areas (Brasil 2014).

Rio de Janeiro was one of the Brazilian States in which CanL was less notified, however, this scenery is currently

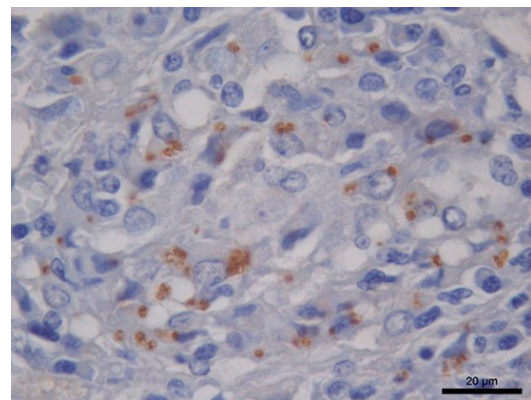


Figure 2. Dog spleen submitted to the immunohistochemical technique showing several brown stained amastigote forms of *Leishmania* sp.

changing and cities like Niterói and Maricá are already notifying cases in domestic dogs, with thirty-eight positive cases being reported in Niterói at the beginning of 2014 (Nunes 2015). Despite the increase in the number of notified cases, Rio de Janeiro State is still considered a low transmission area (Brasil 2014).

Despite living in the proximities of Serra da Tiririca, where the vector was found (Rodrigues *et al* 2013) and recent cases of the disease were described (Paula *et al* 2009, Oliveira *et al* 2015), the dog was from the Northeastern region of Brazil, where CanL is highly incident (Brasil 2014), and lived in this region for most of its life. Due to the slow evolution of the disease and the fact that the dog remained for a few days in the city of Niterói before the clinical symptoms appear, it is possible to determine that the infection occurred in Fortaleza.

Anaemia is a very common condition observed in dogs infected with *Leishmania* sp. On the other hand, leucogram alterations are less frequent (Ribeiro *et al* 2013). Platelets alterations are also described in the process of infection and are present due to coagulation disorders at the hemostasis, changes in medullary production or decrease caused by inflammation (Valladares *et al* 1998).

Significant increase in total proteins dosage is described in seropositive animals. The increase of the globulins fraction occurs because of the anti-*Leishmania* antibodies production. The decrease in the albumin/globulin ratio is expected and frequently described. The increase in hepatic and renal enzymes dosages is common in advanced stage infections and occur because of the deposition of immunocomplexes (Valladares *et al* 1998, Ribeiro *et al* 2018).

Despite the presence of the infection, it was not possible to notice amastigote forms in the splenic parenchyma in both histopathological exams performed by two different specialists, which is not usually described (Tafuri *et al* 2004, Barrouin-Melo *et al* 2006). We believe that chronic inflammation and granulomatous reactions leading to tissue modifications may have complicated the visualisation of parasites. Due to the possibility of diagnosing parasitic antigens *in situ*, the immunohistochemical test was able to increase the detection sensitivity of the etiological agent (Tafuri *et al* 2004).

The presence of amastigote forms in the ascitic liquid of the abdominal cavity was important since it provided evidence to request specific serological exams and to define the diagnosis. This finding is rare, and its real epidemiological role is unknown (Dantas-Torres 2006). The same finding was described in HIV immunodeficient humans (Vicandi *et al* 2000) and the use of an immunosuppressant drug could explain this clinical finding, which was essential to provide an outcome.

Coinfections are common in dogs with leishmaniasis (Cardinot *et al* 2016), aggravating the clinical condition and making difficult to diagnose due to the occurrence of similar clinical symptoms (Cardinot *et al* 2016) and cross-reactions (Valladares *et al* 1998, Barrouin-Melo *et al*

2006). In the present case, the fact that the dog lived in a CanL low transmission area (Brasil 2014) and the veterinarian unfamiliarity with the disease made the diagnosis even more difficult.

The animal died after the diagnosis was confirmed and it was impossible to collect material to identify the *Leishmania* species. However, the epidemiological information related to the animal's origin (Brasil 2014), where it lived (Paula *et al* 2009, Oliveira *et al* 2015), the clinical symptoms, the presence of *Leishmania* sp. in the abdominal cavity and the positive reaction observed at the spleen immunohistochemical test suggests a *Leishmania (Leishmania) infantum* infection.

Canine Leishmaniasis is a silent disease and it easily spreads when there is a suitable environment for the biological vector with the presence of the parasite, hosts, and reservoirs. The diagnosis is essential, especially in low transmission areas where other chronic vector-borne canine diseases exist. As demonstrated in this study, the lack of knowledge and the presence of other infections become a factor that impairs the diagnosis, allowing the infected dog to remain exposed to the vector for longer periods and increasing the propagation of the parasite. This manuscript provides an important contribution to veterinary practitioners and researchers by describing the difficulties of clinical suspicion of *Leishmania* sp. infection in a low transmission area and the importance of detailed history and laboratory investigation before defining a therapeutic intervention.

ACKNOWLEDGEMENTS

The authors would like to thank Tecs Laboratórios for providing technical information about the immunologic tests used in this study. RCM is the recipient of productivity fellowship from CNPq, Brazil. This study was supported by Coordenação de Aperfeiçoamento de Pessoal de Nível Superior (CAPES), Brazil (Finance Code 001).

REFERENCES

- Barrouin-Melo SM, Larangeira DF, de Andrade Filho FA, Trigo J, Julião FS, *et al*. 2006. Can spleen aspirations be safely used for the parasitological diagnosis of canine visceral leishmaniasis? A study on asymptomatic and polysymptomatic animals. *Vet J* 101, 331-339.
- Brasil, Ministério da Saúde. 2014. *Manual de Vigilância e Controle da Leishmaniose Visceral*. Ministério da Saúde, Secretaria de Vigilância em Saúde, Departamento de Vigilância Epidemiológica, Brasília, Brasil, Pp 120.
- Cardinot CB, Silva JE, Yamatogi RS, Nunes CM, Biondo AW, *et al*. 2016. Detection of *Ehrlichia canis*, *Babesia vogeli*, and *Toxoplasma gondii* DNA in the brain of dogs naturally infected with *Leishmania infantum*. *J Parasitol* 102, 275-279.
- Dantas-Torres F. 2006. Presence of *Leishmania* amastigotes in peritoneal fluid of a dog with leishmaniasis from Alagoas, Northeast Brazil. *Rev Inst Med Trop Sao Paulo* 48, 219-221.
- Labarthe N, Pereira MC, Barbarini O, McKee W, Coimbra CA, *et al*. 2003. Serologic prevalence of *Dirofilaria immitis*, *Ehrlichia canis*, and *Borrelia burgdorferi* infections in Brazil. *Vet Ther* 4, 67-75.
- Marcondes M, Day MJ. 2019. Current status and management of canine leishmaniasis in Latin America. *Res Vet Sci* 123, 261-272.

- Marzochi MC, Coutinho SG, Sabroza PC, de Souza MA, de Souza PP, *et al.* 1985. Leishmaniose visceral canina no Rio de Janeiro- Brasil. *Cad Saude Publica* 1, 432-466.
- Nunes VM, Rocha MR, Santos CS, Borges FV, Moutinho FFB. 2015. Situação da leishmaniose visceral canina no Município de Niterói, RJ (2011-2014). Centro de Controle de Zoonoses de Niterói, Rio de Janeiro, Brasil.
- Oliveira AC, Figueiredo FB, Silva VL, Santos FN, Souza MB, *et al.* 2015. Canine visceral leishmaniasis case: investigation in the Jacaré region of Niteroi, Rio de Janeiro, Brazil. *Rev Inst Med Trop S Paulo* 57, 325-332.
- Paltrinieri S, Solano-Gallego L, Fondati A, Lubas G, Gradoni L, *et al.* 2010. Guidelines for diagnosis and clinical classification of leishmaniasis in dogs. *J Am Vet Med Assoc* 236, 1184-1191.
- Paula CC, Figueiredo FB, Menezes RC, Confort EM, Bogio A, *et al.* 2009. Leishmaniose visceral canina em Maricá, Estado do Rio de Janeiro: relato do primeiro caso autóctone. *Rev Soc Bras Med Trop* 42, 77-78.
- Ribeiro RR, da Silva SM, Fulgêncio GO, Michalick MSM, Georges FJ. 2013. Relationship between clinical and pathological signs and severity of canine leishmaniasis. *Rev Bras Parasitol Vet* 22, 373-378.
- Ribeiro RR, Michalick MSM, da Silva ME, Dos Santos CCP, Frézard FJG, *et al.* 2018. Canine Leishmaniasis: An overview of the current status and strategies for control. *Biomed Res Int* 29, 3296893.
- Rodrigues AA, Barbosa V de A, Andrade Filho JD, Brazil RP. 2013. The sandfly fauna (Diptera: Psychodidae: Phlebotominae) of the Parque Estadual da Serra da Tiririca, Rio de Janeiro, Brazil. *Mem Inst Oswaldo Cruz* 108, 943-946.
- Tafuri WL, Santos RL, Arantes RM, Gonçalves R, de Melo MN, *et al.* 2004. An alternative immunohistochemical method for detecting *Leishmania* amastigotes in paraffin-embedded canine tissues. *J Immunol Methods* 292, 17-23.
- Valladares JE, Ruiz De Gopegui R, Riera C, Alberola J, Gállego M, *et al.* 1998. Study of haemostatic disorders in experimentally induced leishmaniasis in Beagle dogs. *Res Vet Sci* 64, 195-198.
- Vicandi B, Jiménez-Heffernan JA, López-Ferrer P, Ortega L, Viguer JM. 2000. Cytologic diagnosis of leishmaniasis in HIV infection. A report of eight cases. *Acta Cytol* 44, 835-839.