

Diagnosis, treatment and outcome following chronic encircling hobbling wounds in a group of working Donkeys in Morocco

Rabiah Azelhak^{a*}, Gigi R. Kay^a, Patrick J. Pollock^b

ABSTRACT. Owners of working equids in Morocco, as in other low and middle-income countries hobble their animals around the pastern using different materials (wire, baling twine and ropes). Resulting wounds are very common and can cause serious damage. Some hobbles even embed into the soft tissue and bony structures of the pastern. Using a retrospective study of The American Fondouk hospital's clinical records, the diagnosis, treatment and outcomes of embedding hobbling injuries are described. From 2012 to 2020, sixteen donkeys were presented suffering from unilateral severe lameness (4/5 to 5/5 lameness on AAEP scale) associated with hobble wounds. Circumferential wounds and/or fibrosis in the pastern were present in all these cases. Because of the suspicion of the presence of wire or baling twine, radiographs of the pasterns of all animals were routinely taken. Ten out of sixteen showed wire in situ encircling the pastern and the others showed a ghost outline of a baling twine hobble with similar periosteal reactions. All animals were treated by surgical removal of the hobble, wound flushing, systemic antibiotics, and bandaging. The outcome was good to excellent in all cases. In these authors' knowledge, this is the first report in the literature of the diagnosis, treatment, and outcome of embedded hobbles in Equidae.

Keywords: Donkey, working equid, Morocco, hobbles, ischaemia, wound.

INTRODUCTION

In Morocco, in common with many low and middle-income countries, working equids are rarely, if ever, kept in paddocks or stabled. Instead, the vast majority rest outside their owners homes while not working, usually restrained by hobbles attached around the pastern.

The choice of equipment used to hobble these animals is often entirely inappropriate and may result in serious injury. The most detrimental hobble type is that made of baling twine or wire as these materials, when neglected or forgotten, can rapidly become embedded within the soft and bony tissues of the limb. These embedded hobbles lead to a significant, and classically recognized, periosteal reaction around the affected bone, and result in severe lameness, however, clinical signs can resolve surprisingly rapidly once the hobble is removed. Despite the fact that the encircling materials are deeply and chronically embedded within the soft and bony tissues of the limb, ischemic necrosis or synovial structure contamination is apparently rarely encountered. This is in stark contrast to other reports in the veterinary literature of acute wire laceration, or entanglement causing prolonged inadequate perfusion in the distal limb, resulting in severe ischaemic damage and even hoof capsule loss (De Gresti *et al.*, 2008; Jackson, 1969; Ruzickova *et al.*, 2017; Stanek, 1981). This retrospective case series describes the presenting signs, diagnosis, treatment and outcome of 16 donkeys

presented to a working equid hospital in Morocco with severe lameness that was associated with hobbles embedded in the soft tissues and/ or the bone of the pastern region.

To the knowledge of the authors, this is the first report of neglected baling twine or wire hobbles embedded around the pastern in equids and yet it is a common and debilitating problem for vast numbers of working equids across the globe. With relatively simple and cheap treatment, the prognosis for affected animals is excellent, in our experience.

MATERIAL AND METHODS

This was a retrospective clinical study and involved a search of the clinical records of all working equids presented to the American Fondouk Hospital in Fez, Morocco, with radiographic evidence of embedded hobbles which was then confirmed at surgery, between 2012-2020.

Any animal presenting with severe lameness plus a draining fistula on the pastern or evidence of scarring or fibrosis around the pastern would routinely be radiographed at this authors hospital, for suspicion of embedded hobbles.

The following information was recorded for each affected case; signalment, reason for presentation, clinical signs, any imaging performed, treatment, type of material used to hobble, length of hospitalisation, outcome, and long term follow up, if available are shown in Table 1.

Radiographs were obtained using a Fujifilm (FCR) capsula system. Latero-medial and/or dorso-palmar/plantar views were available for all cases.

RESULTS

CASE DETAILS

Sixteen cases met the inclusion criteria, and all were adult donkeys with an age range of 2-10 years. All involved

Received: 26.01.2022.

Accepted: 30.06.2022.

^aAmerican Fondouk, Equine charity hospital, Fez, Morocco.

^bUniversity of Edinburgh, Royal (Dick) equine veterinary hospital, Edinburgh, UK.

*Corresponding author: az.rabiah@gmail.com

hobbles around the pastern, 13 of which had been placed on the forelimbs and 2 on the hindlimbs.

There was no mention in the notes for case 16 of which limb was affected. Ten of the donkeys had been hobbled with wire and six with baling twine. Case details and history are presented in Table 1.

HISTORY AND PRESENTING SIGNS

Histories taken from animal owners reported lameness and or discharging tracts dating from one month to as much as one year, and yet most of the owners claimed to be unaware of the continuing presence of the hobble around the pastern. All donkeys were presented with lameness that varied from two weeks to one year. At presentation, the majority were significantly lame at walk (4/5 lameness grade on the AAEP lameness scale). The lesions ranged from small-healed circumferential scars around the pastern with a single draining tract to massive fibrosis and ulceration (Figure 1 A y B).

Radiographic examination identified the presence of wire encircling the pastern in 10 animals (Figure 2 A) and baling twine hobbles, were identified by periosteal changes which suggested the presence of a non- radioopaque foreign body in 6 animals (Figure 2 B).

In the others, bony and periosteal changes ranged from mild new bone formation to extensive changes.

TREATMENT

All embedded hobbles were removed surgically after sedation with xylazine¹ (0.2-0.4 mg/kg) and butorphanol² (0.01mg/kg). In addition, an abaxial sesamoid nerve block was required to anaesthetize the distal limb using 2 ml of lidocaine³ medially and laterally. If a draining tract was present close to the area of the knot as viewed on the radiographs, small curved mosquito forceps were used to localize the wire and exteriorize it such that it could be sectioned. A small incision was then created on the opposite side of the pastern, the hobble exteriorized, and a second cut made through the hobble material so that it could be removed in two sections. The wire or twine was then carefully grasped at the point of the knot and pulled through the overgrown tissue.

Once all hobble material was removed from the wound, the circumferential tract was flushed copiously with sterile saline and an intravenous regional perfusion (IVRP) was performed using ceftiofur (750mg)⁴. The wound was

dressed using a medical grade honey dressing⁵ and a half-limb single layer bandage was placed. The bandages were changed either daily or every other day until wound healing. Excess granulation tissue was not encountered in any of these animals.

All cases were treated with antimicrobials benzylpenicillin procaine⁶ (20000 IU/kg i.m, q12h) with treatment ranging from 4 to 8 days and gentamycin sulphate⁷ (6.6 mg/kg i.v., q24h) with treatment ranging from 3-6 days. All donkeys were treated with flunixin meglumine⁸ (1.1 mg/kg i.v. BID) or phenylbutazone (2.2 mg/kg to 4.4 mg/kg i.v. or p.o., q 12h)^{9,10}. A subcutaneous injection of tetanus antitoxin¹¹ (1500IU) was performed systematically to all treated cases.

OUTCOME

The details of species, wound location, history when available, lameness grade at presentation, post-surgery and at the point of discharge, presence of wire or baling twine, radiographic changes, treatment protocol and number of days hospitalized and outcomes were all recorded and are presented in Table 1.

In all cases recovery after hobble removal was uneventful. The clinical records from our hospital record the post-operative degree of lameness in seven animals. Of these three were completely sound, immediately after hobble removal and two were rated as 2/5 lame at walk. A further two were rated 3/5 lame at walk. Each of these donkeys had presented on the same day as surgery either toe touching or non-weight bearing lame, suggesting that the presence of the foreign body, rather than associated infection or inflammation was the most significant source of pain.

Hospitalization time varied between one week and six weeks with the majority of animals discharged within a month of presentation. Details of the degree of lameness at discharge were available for 13 of the cases. Of these all were considered by the treating veterinarian to be sound enough to return to work in the context of a working equid. Five were recorded as sound, six as 2/5 and one was reported to have a residual lameness of 3/5 although even that individual returned to work effectively.

⁵ Jorgan Kruuse A/S, Denmark.

⁶ KELA N.V. Belgium.

⁷ Provet , Rabat, Morocco.

⁸ Livisto, El Salvador.

⁹ Vétroquinol, France

¹⁰ Atlas vétérinaire, Casablanca, Morocco.

¹¹ Serum institute of India , Hadapsar.

¹ Aspen Veterinary Resources, USA.

² Merck Animal Health, Germany.

³ Vetoquinol, France.

⁴ Aspen Veterinary Resources, USA.

Table 1. Clinical information of cases in the study.

Case Number	Duration of lameness at presentation	Limb affected	Lameness at presentation	Wound Description	Radiographic findings	Hobble material	Treatment	Lameness post surgery	Lameness at hospital discharge	Duration of hospitalisation
Case 1	2 weeks	LF pastern	4/5 lame	Circumferential wound	Full circumferential soft tissue defect	Baling twine	Baling twine removed, 3 IVRP	NI	Sound	8 days
Case 2	NI	RF pastern	4/5 lame	Circumferential wound with draining tract laterally	Periosteal reaction P1 + baling twine outline	Baling twine	Baling twine removed, 2 IVRP	NI	2/5 lame	21d
Case 3	1 year	RF pastern	4/5 lame	Circumferential wound +extensive fibrosis + bone exposure	Periosteal reaction P1 + baling twine outline	Baling twine	Baling twine removed, no IVRP mentioned	2/5 lame	2/5 lame	25d
Case 4	4 months	RF Pastern	NI	Circumferential wound	Periosteal reaction P1	Baling twine	Baling twine removed, 2 IVRP	3/5 lame	NI	34 d
Case 5	3 months	LF Pastern	4/5 lame	Circumferential wound	Periosteal reaction P1+ baling twine outline + foreign body visible	Baling twine	Baling twine removed, no IVRP	NI	2/5 lame	19 d
Case 6	2 month	RF pastern	4/5 lame	Circumferential extensive fibrosis and scarring with a single draining tract laterally	Periosteal reaction P1 + baling twine outline	Baling twine	Baling twine removed, 3 IVRP	Sound at walk	Sound	40 d
Case 7	> 4 month	LH4 pastern	5/5 lame	Circumferential scarring with single draining tract dorsally	Periosteal reaction P1 + wire visible	Wire	Wire removed, 4 IVRP	2/5 lame	3/5 lame	20 d
Case 8	2 weeks	RF pastern	5/5 lame	Circumferential wound with draining tracts	Periosteal reaction P1+ wire visible	Wire	Wire removed, 3 IVRP	Sound at walk	Sound	20d
Case 9	NI	RF pastern	4/5 lame	Circumferential wound with single draining tract dorsally	Periosteal reaction P1+ significant Defect	Wire	Wire removed 3 IVRP	3/5 lame	2/5 lame	33d

Case Number	Duration of lameness at presentation	Limb affected	Lameness at presentation	Wound Description	Radiographic findings	Hobble material	Treatment	Lameness post surgery	Lameness at hospital discharge	Duration of hospitalisation
Case 10	NI	RF3 pastern	5/5 lame	Circumferential wound	Periosteal reaction P1+wire visible	Wire	Wire removed 3 IVRP	NI	2/5 lame	54D
Case 11	NI	LF pastern	4/5 lame	Circumferential wound with a single draining tract dorsally	Periosteal reaction P1	Wire	Wire removed 3 IVRP	NI	NI	10d
Case 12	NI	RF pastern	4/5 lame	Circumferential fibrosis and scarring with single draining tract laterally	Periosteal reaction P1 + wire visible	Wire	Wire removed, 3IVRP	Sound at walk	Sound	10 d
Case 13	NI	RF pastern	4/5 lame	Circumferential wound	Periosteal reaction P1+ significant defect	Wire	Not mentioned	NI	NI	28d
Case 14	NI	LF3 pastern	4/5 lame	Circumferential wound	Periosteal reaction P1 + wire visible	Wire	Wire removed 3 IVRP	NI	Sound	NI
Case 15	NI	RH4 pastern	5/5 lame	Circumferential scarring with single draining tract dorsally	NI	Wire	Wire removed, no IVRP mentioned	NI	2/5 lame	NI
Case 16	NI	NI	4/5 lame	Circumferential fibrosis with single draining tract dorsally	Periosteal reaction P1+ significant defect+wire visible	Wire	Wire removed, 2 IVRP	NI	NI	NI

NI: no information available.
IVRP: Intravenous Regional perfusion.

DISCUSSION

Working equids, that is horses, donkeys and mules, play a critical role in supporting the income generating capacity of their owners in low and middle income countries and are essential in both agricultural and urban arenas (Fielding, 1991). Poor management strategies, as a result of ignorance and poverty, are at the root of many of the health problems encountered in this population (Lindberg *et al.*, 2003). The incorrect use of hobbles, or the use of incorrect material for making hobbles, is one example of poor management (Kay & Ouassat, 2002).

The use of hobbles for containing working equids is ubiquitous in Morocco and in many other countries in the developing world where access to paddocks is limited (Pritchard *et al.*, 2005). The use of these hobbles entails many risks. All over the world, the safe containment of horses poses challenges. Post and rail paddocks probably represent the gold standard in horse containment and yet even this type of fencing can lead to injuries. In one survey of 180 horse owners run by The Equine Research Centre in Guelph Ontario, 27% of respondents reported accidents caused by fencing, of which 63% were caused by wire fencing and 13% caused by post and rail (Virginia Cooperative Extension, 1999). In many developing world countries, these containment issues are hugely compounded by the fact that access to grazing is transient and temporary and therefore paddocks are largely unknown. Instead, working equids are more often than not, kept tied up, often on long ropes to allow maximum grazing, and left unsupervised outside to forage. In Morocco, entanglement in these grazing ropes is very common and the resultant acute injuries range from mild rope burns to catastrophic lesions with associated musculoskeletal problems including torticollis and fractures. Attaching grazing animals using hobbles around the pasterns causes chronic limb lesions ranging from mild abrasions to tendonitis, laceration, ischaemia and tetanus (Kay *et al.*, 2004).

Previous studies in working equid populations from a number of low and middle-income countries have shown that nearly all working equids have visible lesions or scars from hobbles. In Ethiopia a study of 497 equids reported 98-100% of animals had hobble lesions (Mekuria *et al.*, 2013) and in a multi country study from Afghanistan, India, Egypt, Jordan and Pakistan involving over 4000 animals, between 62 and 88.8% of animals showed lesions or scars from hobbles (Pritchard *et al.*, 2005). In Morocco a study of 1713 equids showed 10% of animals with current lesions and a further 20% with evidence of previous lesions (Kay & Ouassat, 2002).

The severity of the lesions associated with hobbling the limb of an individual animal will depend on the material used for the hobble and how long the hobble is left on (Kay & Ouassat, 2002). In the 16 cases reported here, hobbling had been carried out with baling twine or wire, the cheapest, most readily available and probably

most inappropriate of materials. Hobbles are sometimes left on the animal permanently, irrespective of underlying inflammation and this explains how these hobbles, with time, had come to embed themselves deeply within the soft tissues of the pastern.

Diagnosing the presence of an embedded hobble is reasonably straightforward. Presenting signs are almost pathognomonic and all equids suspected of having embedded hobbles were subject to radiographic views. All the donkeys in this case series presented with one or all of the following signs: a small draining tract at the level of mid pastern, an associated circumferential lesion (Figure 1 A), which may have been almost entirely healed by the time of presentation or may show massive soft tissue proliferation and severe lameness (4/5 to 5/5 on AAEP lameness scale). The severe lameness was a feature of all the animals in this case series. Notably the hobble could not be visualized, nor palpated at the skin surface on any of our cases. Radiography confirmed the diagnosis in all cases with wire hobbles (Figure 2 A) and in all but one of the animals with a baling twine hobble, periosteal changes were evident that suggested the presence of a non-radio-opaque foreign body (Figure 2 B). The majority of the cases presented here had evidence of massive periosteal and bony reactions to the presence of the foreign body, both wire and baling twine. An image of the first phalanx of a donkey that had presented many years previously and been euthanased prior to hobble removal shows the typical effect of this wire on the periosteum of the pastern (Figure 2 C).

Embedded hobbles are a problem of equids in low and middle income countries where most veterinarians will not have access to radiography, however the clinical picture is so consistent that even without radiographic evidence, exploring the pastern for an embedded hobble would be worthwhile in any equid presenting with the clinical signs described here. Once diagnosed, treatment is remarkably simple and effective and requires no special equipment or even hospitalization. Recovery can be dramatic with many animals being immediately sound after removal of the foreign body, and all of our cases were discharged as sound enough to be useful as a working equid. There was no evidence in any of our cases that the hobble had penetrated any joint or synovial structure. Any joint contamination or osteomyelitis would be expected to result in severe lameness even after hobble removal which was not the case in our series of animals. Similarly, there was no evidence of associated tendon injury despite radiographic evidence that indicated extreme constriction and even penetration of the cortex (Case 1 and Case 14). Any palmar constriction around the pastern might logically have been expected to lead to tendon transection, tendon laceration or severe tendonitis, however, post-surgery, no individual showed any evidence of loss of support to the limb, or alteration in posture or function, any of which would be indicative of severe tendon injury or transection. Complete tendon



Figure 1. A) Circumferential wound on the right hind pastern with a draining tract and soft tissue swelling around and above the hobbling materiel (wire in this case); B) Extensive circumferential fibrosis with severe swelling (the hobbling materiel in this case was a bailing twine).

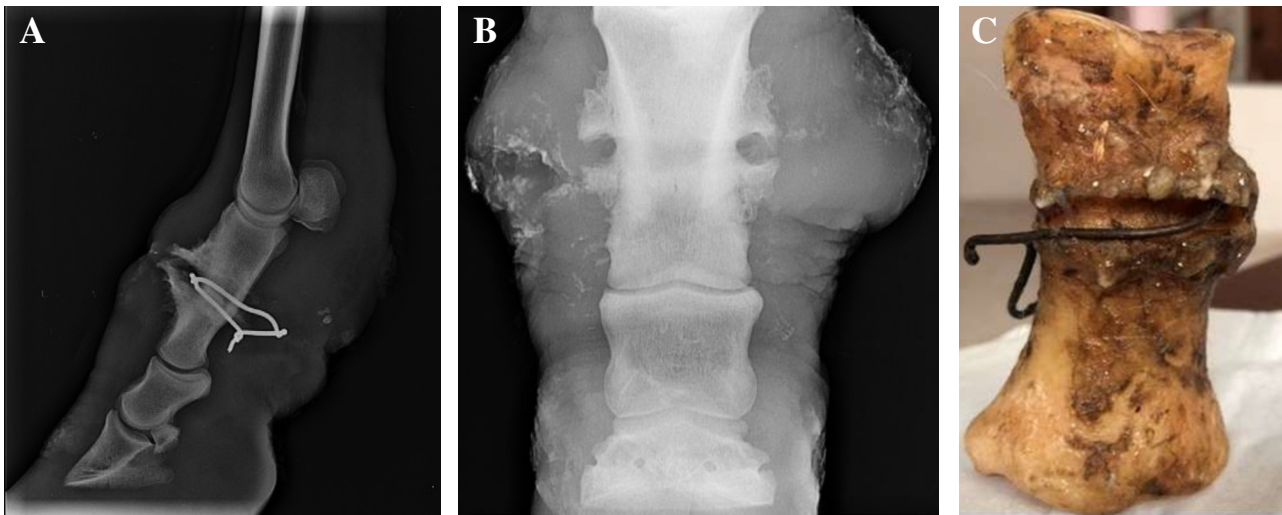


Figure 2. A) Latero-medial radiographic projection of the right forelimb. Note the encircling radiopaque foreign body at the mid first phalanx with extensive periosteal reaction; B) Dorso-palmar view of the right forelimb first phalanx with axial and abaxial extensive periosteal reaction forming an outline of the embedded foreign body (baling twine); C) Post mortem findings of a donkey with embedded wire in the pastern associated with extensive periosteal reaction.

transection is associated with significant alterations in limb conformation under loading, although partial severance or tears may not alter tendon function (Smith, 2008). Because of this, palpation of the palmar or plantar aspect of the

pastern was routinely performed once wound healing was complete and if the animal remained lame.

Donkeys showing evidence of heat or pain focused on the palmar aspect of the pastern would have an ultrasonographic

assessment. None of the animals that were evaluated showed any discernible tendon abnormality either in shape or size, however longitudinal tears of the DDFT are often difficult to assess ultrasonographically (Smith, 2008) and the very small size of the donkey pastern makes ultrasonography of this region challenging. The existence of tendon tears or mild tendonitis cannot therefore, be completely ruled out as a cause of the mild residual lameness that was seen in 7 of our cases at discharge.

Localized infection was evident in most of our cases although generally this was restricted to the pastern. The extensive cellulitis, that is a common sequelae to many distal limb injuries in horses (Ruzickova *et al.*, 2017), was not evident in any of our cases, although all were treated with distal limb IVRP and/or systemic broad spectrum antibiotics as a precautionary measure. Many donkeys presenting with embedded hobbles had few external wounds except for single draining tracts, and wound treatment in these cases was restricted to flushing the tract after wire or twine removal, followed by bandaging as support and prevention of further contamination. Where cutaneous wounds were evident, sterile Manuka honey dressings were applied and changed daily. Whilst the evidence for the use of medical grade honey is somewhat conflictual, it has been shown in several recent studies on iatrogenically inflicted wounds on both forelimbs, that application of Manuka honey dressings reduces wound area by reducing retraction and that treated wounds remain smaller than contralateral controls and heal faster overall (Bischofberger *et al.*, 2011; 2013).

It is hypothesized that Manuka honey owes its antibacterial properties to a number of factors, most important of which are the small quantities of hydroperoxide and methylglyoxal (MGO) otherwise known as UMF - Unique Manuka Factor. These factors combined with the low pH (around 4) of honey inhibit bacterial growth and potentially stimulate fibroblastic activity (Carnwarth *et al.*, 2014). Contaminated sloughing and necrotic wounds, particularly those which require ongoing debridement are ideal candidates for the use of medical grade Manuka Honey (Carnwarth *et al.*, 2014) and this made it the dressing of choice for the more severe cutaneous wounds in our group of donkeys. The downside of this dressing is cost and availability. Manuka honey dressings are a relatively expensive option in a working equid context and not available in many developing world countries. Localized infection was evident in most of our cases although generally this was restricted to the pastern. The extensive cellulitis that is a common sequelae to many distal limb injuries in horses (Ruzickova *et al.*, 2017), was not evident in any of our cases, although all were treated with distal limb IVRP and/or systemic broad spectrum antibiotics as a precautionary measure.

Some hobbling injuries can be associated with fatal outcomes, either through fractures or the development of tetanus, particularly so in parts of the world where working

equids are not routinely vaccinated. All animals in this case series were treated with tetanus antitoxin as hobble lesions have been reported as one of the main causes of tetanus infection amongst working equids. In one study of 56 equids with tetanus, and 7 animals were thought to have developed tetanus through contamination of hobble lesions (Kay & Knottenbelt, 2007).

Distal limb lacerations, in all equidae, frequently involve vascular compromise with subsequent ischaemic damage and even sloughing of the hoof capsule (Ruzickova *et al.*, 2016). In our series despite the apparent tightness and bilateral constriction of the hobble identified radiographically in most animals, hoof sloughing or ischaemic damage was not a feature. It is probable that the chronic, insidious, nature of vascular compromise associated with hobbling allowed the development of alternative vasculature. Indeed, it has been shown that collateral vessels can develop in the 2-4 weeks following vascular damage (Keen *et al.*, 2008) and this adaptability may have been protective in these cases. Imaging modalities such as digital venography or arteriography have been used to visualize the vascularity of the equine digit (Redden, 2001; Walker *et al.*, 2017) and it would have been interesting to evaluate any compromise of the vessels of the digit in our cases.

The species distribution of our case series is notable. Despite having a case load in this hospital of approximately equal numbers of horses, mules and donkeys, it is only donkeys that have ever been presented with hobbles embedded around the pastern. This may be a function of their intrinsic value; being of less value than the horse or mule, less care is taken over their wellbeing. Or alternatively it may be a function of their stoic nature; owners may feel that they are less likely to cause themselves harm therefore less care is required in their maintenance and therefore owners may choose to use wire rather than a more appropriate material. It is also striking that in both of the studies on the incidence of hobbling lesions, donkeys are much more likely to show lesions than horses or mules. In the Pritchard study, 88.8% of donkeys had lesions or scars compared with 62% of horses and, in the Kay study from Morocco, 45% of donkeys as opposed to 28% of horses showed lesions or scars. This is some indication that owners will expend more thought and care on the choice of hobble materials for more valuable animals and that there is some understanding of the risks of using wire and twine to tether horses. Much work has been done in various countries and by various Governmental and non-governmental organizations to educate owners on improved hobbling practices and limit the devastating consequences of this poor management practice.

A program of owner education and supply of appropriate non traumatic hobbles has been in place for many years in Morocco, set up by this author at working equid clinics throughout the country (Kay & Ouassat, 2002). Although it is clear that much benefit to welfare can be achieved through educating owners on the use of non-traumatic

hobble material such as thick cotton rope, it is much more challenging to suggest a cost effective means of allowing animals to graze that does not rely on long grazing ropes. An obvious answer would be to use electric fencing which would allow animals to temporarily graze different areas. Unfortunately, the cost involved in purchasing such a set up would make this unworkable for the vast majority of working equid owners.

In conclusion, this is the first report on the treatment and successful outcome of a group of working donkeys treated for chronic encircling hobbling injuries of the distal limb. Clinicians treating working equids, should be aware of the clinical signs, classical radiographic appearance, even in the absence of radio-opaque hobbling material, and excellent prognosis following treatment despite severe presenting clinical signs.

COMPETING INTERESTS STATEMENT

The authors declare that they have no competing interests.

ETHICAL STATEMENT STUDIES

A verbal consent form was obtained from animal's owners.

SOURCE OF FUNDING

None.

REFERENCES

- Bischofberger, S. A., Dart, C.M., Perkins N. R., & Dart, A. J. (2011). A preliminary study on the effect of Manuka honey on second-intention healing of contaminated wounds on the distal aspect of the forelimbs of horses. *Veterinary Surgery*, 40(7), 898-902. <https://doi.org/10.1111/j.1532-950X.2011.00886.x>
- Bischofberger, S. A., Dart, C. M., Perkins N.R., Kelly, A., Jeffcott, L., & Dart, A. J. (2013). The effect of short and long-term treatment with manuka honey on second intention healing of contaminated and non-contaminated wounds on the distal aspect of the forelimbs in horses. *Veterinary Surgery*, 42(2), 164-160. <https://doi.org/10.1111/j.1532-950X.2012.01083.x>
- Carnwath, R., Graham E. M., Reynolds, K., & Pollock P. J. (2014). The antimicrobial activity of honey against common equine wound bacterial isolates. *Veterinary Journal*, 199(1), 110-114.
- De Gresti, A., Zani, D. D., D'Arpe, L., & Scandella, M. (2008). A singular case of traumatic total hoof capsule avulsion. *Equine Veterinary Education*, 2(8), 406-410. <https://doi.org/10.2746/095777308X332240>
- Fielding D. (1991). The number and distribution of equines in the world. In: Proceedings of the Colloquium on Donkeys, Mules and Horses in Tropical Agricultural Development, Edinburgh, 3-6 September, pp. 62-66.
- Jackson, L. L. (1969). Regrowth of an equine hoof following traumatic removal. *Iowa State University Veterinarian*, 31(2), 1.
- Kay, G., & Knottenbelt, D. C. (2007). Tetanus in equids: A report of 56 cases. *Equine Veterinary Education*, 19(2), 107-112. <https://doi.org/10.2746/095777307X181320>.
- Kay, G., & Ouassat, M. (2002). Preventing hobble injuries-Experiences with a hobble distribution programme in Morocco. In: Proceedings of 4th International Colloquium on Working Equines, Eds: A. Pearson, D. Fielding and D. Tabaa, SPANA, London. pp. 190-191.
- Keen, J. A., Hillier, C., McGorum, B. C., & Nally, J. E. (2008). Endothelin mediated contraction of equine lamellar veins. *Equine Veterinary Journal*, 40(5), 488-492. <https://doi.org/10.2746/042516408X313634>
- Lindberg, A. C., Leeb, C., Pritchard, J.C., Whay, H. R., & Main, D. C. J. (2003). Determination of welfare problems and their perceived causes in working equines. In: Proceedings of the Universities Federation for Animal Welfare Symposium, Edinburgh, 2-4 April, p. 247.
- Mekuria, S., Mulachew, M., & Abebe, R. (2013). Management practices and welfare problems encountered on working equids in Hawassa town, Southern Ethiopia. *Veterinary Medicine and Animal Health*, 5(9), 243-250. <https://doi.org/10.5897/JVMAH10.017>
- Pritchard, J. C., Lindberg, A. C., Main, D. C. J., & Whay, H. R. (2005). Assessment of the welfare of working horses, mules and donkeys, using health and behaviors parameters. *Preventive Veterinary Medicine*, 69(3-4), 265-283. <https://doi.org/10.1016/j.prevetmed.2005.02.002>
- Redden, F. (2001). Possible therapeutic value of digital venography in two laminitic horses. *Equine Veterinary Education*, 13(3), 125-127. <https://doi.org/10.1111/j.2042-3292.2001.tb00076.x>
- Ruzickova, P., Trencart, P., & Laverty, S. (2017). Spontaneous hoof capsule loss following lacerations of the equine distal limb. *Equine Veterinary Education*, 29(9), 472-477. <https://doi.org/10.1111/eve.12597>
- Stanek, C. Brkic, A. (1981). Volständige, traumatisch bedingte exungulation mit offener fraktur beider hufbeinaste bei einem pferd. *Tierärztliche Praxis*, 8, 481-488.
- Lawrence, L. A. (1999). Fence Safety Survey, Virginia Cooperative Extension. https://www.sites.ext.vt.edu/newsletter-archive/livestock/aps-99_04/aps-0051.html
- Smith, R. K. W. (2008). Tendon and ligament injury. In: Proceedings AAEP, In-depth: Tendon and ligament injury. 54, 475-501.
- Walker, W. T., Ducharme, N. G., Tran, J., & Scrivani, P. V. (2017). Nonselective computed tomography angiography for detecting arterial blood flow to the distal limb following trauma in two small equids. *Equine Veterinary Education*, 29(1), 15-21. <https://doi.org/10.1111/eve.12227>